Supplemental Materials of

A FreeSurfer MRI Von Economo – Koskinas Atlas

Authors

Lianne H. Scholtens[1], Marcel A. de Reus[1], Siemon C. de Lange[1], Ruben Schmidt[2], Martijn P. van den Heuvel[1]

Affiliations

[1] Brain Center Rudolf Magnus, Department of Psychiatry, University Medical Center Utrecht, The Netherlands

[2] Brain Center Rudolf Magnus, Department of Neurology, University Medical Center Utrecht, The Netherlands

Address for Correspondence

Martijn van den Heuvel, Brain Center Rudolf Magnus, Department of Psychiatry, University Medical Center Utrecht, Heidelberglaan 100, 3508 GA Utrecht, PO Box 85500, Room: A01.126, The Netherlands; Phone: +31 88 75 58244; Fax: +31 88 75 55443; Email: M.P.vandenheuvel@umcutrecht.nl

Supplementary Methods

Data demographics

Von Economo and Koskinas based their mappings on detailed analysis and observations of several healthy brain samples. In their 1925 writings, they state (page 8 (von Economo and Koskinas, 1925)):

"Wir haben natürlich von vornherein immer bloß Gehirne von Personen in den Kreis unserer Untersuchungen gezogen, welche von jeder geistigen Abnormität frei waren und überhaupt keine Symptome von selten des Nervensystems geboten hatten…",

which in English translates to:

"We have of course from the beginning only included brains in our research of people who were without psychiatric abnormalities and displayed no neurological symptoms…"

They do not explicitly mention the number of specimens included in their research, but about the quantitative regional morphological data presented they state (page 34):

"Das Bild stellt ein Durchschnittsresults vieler Rindenmessungen an zahlreichen Gehirnen schematisch dar, welche wir immer an homologen Stellen der Hemisphären vorgenommen haben." [*"The illustration shows the average result of many cortical measurements done at homologous locations in hemispheres of numerous brains."*]

Although Von Economo and Koskinas further do not specifically mention the exact age of the subjects included in their study, they selected their subjects within the age range of 30-40 years, writing (page 41):

"Nochmals möchten wir hier erwähnen, daß sich alle unsere Befunde auf Gehirne Erwachsener, im 4. Lebensdezennium stehender Personen beziehen." [*"We would like to again mention that all our results are from adult brains of individuals in their 4th decade of life."*]

Furthermore, as they mention that they did not have sufficient information to draw conclusions on gender or hemispheric differences, it is highly likely that they included information on left and right hemispheres of male as well as female donors (page 284): *"nur eines möchten wir hier speziell erwähnen, daß wir betreffs der Unterschiede, die BETZ zwischen rechts und links an den Hemisphären gemacht hat, sowie zwischen männlichen und weiblichen Gehirnen, keine die betreffenden Aussprüche dieses Autors bestätigenden Resultate erhalten haben; vielleicht war es ein Zufall, daß gerade die weiblichen Gehirne, die ich untersucht habe, vielfach eine schönere Ausbildung betreffs Größe sowohl als Form der Pyramidenzellen aufgewiesen haben als die männlichen."* [*"We would like to specially mention that regarding the differences BETZ [Vladimir Betz (1834-1894), pioneering neuroanatomist after whom the giant pyramidal cells in the primary motor cortex were named (Betz, 1874)] found between the right and left hemisphere, as well as between male and female brains, we have not been able to confirm any of his statements; maybe was it a coincidence that precisely those female brains that I examined frequently had a more beautiful formation regarding size and shape of the pyramidal cells than the male brains."*]

References

Betz W. (1874): Anatomischer nachweis zweier gehirncentra. Zentralbl Med Wiss 12(578,595).

von Economo CF, Koskinas GN. 1925. Die cytoarchitektonik der hirnrinde des erwachsenen menschen: J. Springer.

Supplemental tables

Von Economo – Koskinas abbreviation	Full region name
FA	Area praecentralis
FB	Area frontalis agranularis
FC	Area frontalis intermedia
FCBm	Area (frontalis intermedio agranularis magnocellularis in) Broca
FD	Area frontalis granularis
FDdelta	Area frontalis granularis media
FDT	Area frontalis granularis triangularis
FE	Area frontopolaris
FF	Area orbitalis (granularis)
FG	Area gyri recti (Ar. recta)
FH	Area praefrontalis
FJK	Area frontoinsularis + Area piriformis frontalis
FLMN	Area parolfactoria + Area geniculata + Area praecommissuralis
HA	Area uncinata
HB	Area parauncinata
HC	Area rhinalis limitans
IA	Area insulae praecentralis
IB	Area insulae postcentralis
LA1	Area limbicus anterior agranularis - praecingularis
LA2	Area limbicus anterior agranularis - cingularis anterior
LC1	Area cingularis posterior dorsalis
LC2	Area cingularis posterior ventralis
LC3	Area cingularis limitans posterior
LD	Area retrosplenialis agranularis
LE	Area retrosplenialis granulosa
OA	Area peristriata
OB	Area parastriata
OC	Area striata (granulosa)
PA	Area postcentralis gigantopyrimidalis + Area postparacentralis gigantopyrimidalis
PB	Area postcentralis oralis simplex + Area postcentralis oralis granulosa
PC	Area postcentralis intermedia
PD	Area postcentralis caudalis
PE	Area parietalis superior

PF	Area supramarginalis
PG	Area angularis
PH	Area parietalis (temporo-occipital) basalis

Von Economo – Koskinas region	**Region border description**
TA	Area temporalis superior
TB	Area supratemporalis magnocellularis simplex
TC	Area supratemporalis granulosa
TD	Area supratemporalis intercalata
TE	Area temporalis propria
TF	Area fusiformis
TG	Area temporoporalis

Supplemental Table S1. List of abbreviations and region names. The table details the region names included in the FreeSurfer Von Economo – Koskinas atlas in the left column, and their precise region desciption in the right column. For each short region name, the first letter indicates the cerebral lobe the region belongs to (F-frontal, H-hippocampal, I-insular, L-limbic, O-occipital, P-parietal, T-temporal).

FA	Laterally this region covers most of the precentral gyrus, its anterior border overlaps with the precentral sulcus and its the inferior end continues further down to the Sylvian fissure. The posterior region border is formed by the central sulcus, the inferior border by the sulcus subcentralis. On the medial aspect of the hemisphere the anterior region border is formed by the paracentral sulcus, with the inferior border at the sulcus callosomarginalis. The posterior border on the medial side runs through the fossa paracentralis.
FB	On the lateral aspect of the brain, the anterior border of this region has been drawn in a straight line up from the sulcus frontalis inferior (starting at the level of the sulcus diagonalis operculi) to the dorsal aspect of the hemisphere and from there down on the medial side to the first branching of the sulcus callosomarginalis. The inferior border is defined by the Sylvian fisssure. Posteriorly (on the lateral aspect of the hemisphere), the region is bordered by the precentral sulcus, medially the border runs along the paracentral sulcus until it reaches the sulcus callosomarginalis.
FC	The anterior border of this region is drawn as a line going up from the sulcus frontalis inferior along the anterior end of the sulcus frontalis medius to the dorsal aspect of the hemisphere. From there the same line continues down to the sulcus intralimbicus, passing the posterior branches of the sulcus callosomarginalis on its way. The posterior border of this region has been drawn as a line starting at the sulcus frontalis inferior just above the sulcus diagonalis operculi going up to the dorsal aspect of the hemisphere and from there down on the medial side to the first branching of the sulcus callosomarginalis.
FCBm	This region covers the pars opercularis, bordered on two sides by the Sylvian fissure and its vertical ramus. The other two borders are formed by the inferior branch of the precentral sulcus and the sulcus frontalis inferior.
FD	This region spans a large portion of the frontal lobe. Laterally, its posterior border is formed by a line drawn up from the sulcus frontalis inferior along the anterior end of the sulcus frontalis medius to the dorsal aspect of the hemisphere. From there the same line continues down to the sulcus intralimbicus, passing the posterior branches of the sulcus callosomarginalis on its way. Starting on the medial surface of the hemisphere, its inferior border is drawn as a drawn as a straight line spanning medially from the most anterior point of the cingulate gyrus to the end of the sulcus orbitalis lateralis on the lateral surface. The posterior border on the lateral surface is formed by the sulcus frontalis inferior and by a line connecting the two ends of the ramus verticalis and horizontalis Sylvii. The final border on the medial

	aspect is defined as the sulcus intralimbicus.
FDdelta	The borders of this region are ambigous. The region has been taken to be on the center of the medial frontal sulcus.
FDT	This region covers the gyrus triangularis. It is delineated on three sides by the Sylvian fissure and its ramus verticalis and horizontalis. The fourth border is formed by a line drawn between the ends of both rami.
FE	This region covers the pole of the frontal lobe, on the lateral as well as the ventral and medial sides of the hemisphere. On the ventral surface the posterior border of this region runs from the junction of the sulcus orbitalis lateralis and transversalis to the anterior tip of the gyrus rectus. Medially, the inferior border is drawn from the anterior tip of the gyrus rectus to the most inferior point of the cingulate cortex and the superior border is drawn as a straight line spanning medially from the most anterior point of the cingulate gyrus to the end of the sulcus orbitalis lateralis on the lateral surface. Laterally, the inferior border of the region runs from the anterior tip of the gyrus rectus to the end of the ramus horizontalis fissurae Sylvii.
FF	This region occupies a large part of the ventral surface of the frontal lobe and extends from the sulcus olfactorius on the ventral aspect up to the lateral aspect until it reaches the ramus horizontalis fissurae Sylvii. On the ventral aspect its anterior border is drawn as a line spanning from the junction of the sulcus orbitalis lateralis and transversalis to the anterior tip of the gyrus rectus, its posterior border is formed by the margo anterior. On the lateral surface of the hemisphere its anterior border is drawn up from the anterior tip of the gyrus rectus to the end of the ramus horizontalis fissurae Sylvii.
FG	Situated on the anterior ½ of the gyrus rectus, the posterior border of this region is drawn as a line perpendicular to the axis of the gyrus rectus. Medially the region extends from the gyrus rectus onto the orbitofrontal cortex, up to the sulcus rostralis superior.
FH	Located on the medial and ventral aspect of the frontal lobe, the anterior border of this region is drawn as a straight line from the cingulate sulcus to the most anteriosuperior point of region FG and from there follows the sulcus rostralis superior; at 1/3 of the distance to the edge of the cortical mantle the line diverges diagonally to the ventral aspect of the gyrus rectus, where it continues in a straight line across the gyrus rectus (at 1/2 of the length of the gyrus) to the sulcus olfactorius. Its posterior border is drawn as a line perpendicular to the axis of the gyrus rectus at 5/6 of the rosto-caudal length of the gyrus. Superiorly the region

	is bordered by the cingulate sulcus, inferiorly by the sulcus olfactorius.
FJK	This region is situated in the fold between the insular cortex and the edge of the frontal cortex.
FLMN	This region is located on the most caudoinferior edge of the frontal cortex. The extend of this region runs from the cingulate culcus to by the edge of the gyrus rectus and the edge of the orbitofrontal gyrus. The region occupies the most caudal 5/6th of the gyrus rectus and its border on the medial aspect of the hemisphere is formed by the sulcus olfactorius.
HA	This region occupies the uncus of the hippocampal gyrus and has been segmented to occupy the thickest portion of the anterior part of the hippocampal gyrus. Superiorly this region is delineated by the sulcus hippocampi. The inferior border is drawn from the most posterior edge of the uncus in a diagonal line (in anterior direction) to the fissura rhinalis.
HB	Located on the hippocampal gyrus, the anterior border of this region is drawn from the most posterior edge of the uncus in a diagonal line anteriorly to the fissura rhinalis. Posteriorly, the border is drawn from the most posterior edge of the uncus in a straight line down to the fissura rhinalis. Superiorly, the border is defined as the sulcus hippocampi, inferiorly as the fissura rhinalis.
HC	Situated on the hippocampal gyrus, the anterior border of this region was drawn from the most posterior edge of the uncus in a straight line down to the fissura rhinalis. Posteriorly, the region is delimited by the edge of the hippocampal gyrus, taken as the point where the "truncus fissurae parietooccipitalis et calcarinae" ends. Superiorly, the border is defined as the sulcus hippocampi, inferiorly as the fissura rhinalis.
IA	Located on the anterior part of the insular gyrus, the anterior border of this region is formed by the sulcus brevis primus insulae, while the posterior border is formed by the sulcus centralis insulae. All other borders are defined as the edge of the insular gyrus.
IB	Located on the posterior part of the insular gyrus, the anterior border of this region is formed by the sulcus centralis insulae. All other borders are defined as the edge of the insular gyrus.
LA1	Situated on the upper anterior portion of the cingulate cortex, the posterior border of this region is formed by a line drawn just anterior of the paracentral sulcus, diagonally (in anterior direction) to the sulcus corporis callosi. The superior border is

	most anteriorly (up to the gyrus frontolimbicus anterior) defined as the sulcus intralimbicus, from there the border coincides with the sulcus callosomarginalis. The inferior border of this region is formed by a line drawn at 1/5 of the width of the cingulate gyrus removed from the superior border; dividing the anterior cingulate cortex into two elongated ribbons.
LA2	Situated on the lower half of the anterior portion of the cingulate cortex. Its posterior border is formed by the a line drawn just anterior of the paracentral sulcus, diagonally (in anterior direction) to the sulcus corporis callosi. Its superior border is a line drawn a distance of 1/5 of the width of the anterior cingulate gyrus away from the sulcus intralimbicus and de sulcus callosomarginalis; dividing the anterior cingulate cortex into two elongated ribbons. The inferior border is the sulcus corporis callosi.
LC1	Situated on the caudal portion of the cingulate cortex and part of the medial superior parietal cortex. The anterior border of this region is formed by the ramus verticalis sulci callosomarginalis. Posterially, the region is bordered by the fissura parietooccipitalis. The superior border of this region is drawn as a curved line drawn in anterior direction from the most superior point of the sulcus subparietalis to the start of the ramus verticalis sulci callosomarginalis and in posterior direction to the fissura parietooccipitalis at the level of the anterior end of the sulcus sagittalis cunei inferior. The region's superior border was traced from the sulcus callosomarginalis at the level of the Fossa paracentralis in a curved line to the anterior tip of the sulcus subparietalis and from there to a point just below the posterior tip of the sulcus subparietalis, after which it continues to the "truncus fissurae parietooccipitalis et calcarinae".
LC2	This region is situated on the caudal portion of the limbic lobe. Its anterior border divides the cingulate cortex just anterior of the paracentral sulcus, diagonally (in anterior direction) to the sulcus corporis callosi. Its posterior border is formed by the truncus fissurae parietooccipitalis et calcarinae. The region's superior border is less obvious, it was traced from the sulcus callosomarginalis at the height of the Fossa paracentralis in a curved line to the anterior tip of the sulcus subparietalis and from there to a point just below the posterior tip of the sulcus subparietalis, after which it continues to the "truncus fissurae parietooccipitalis et calcarinae". The inferior border is for the most anterior portion of the region formed by the sulcus corporis callosi. More posteriorly the border diverges away from the sulcus corporis callosi towards the truncus fissurae parietooccipitalis et calcarinae.
LC3	This small region occupies a portion of the gyrus intralimbicus

	and a small edge of the limbic gyrus, bordered anteriorly at the same hight as region LC2 and posteriorly at the height of the fossa paracentralis.
LD	Occupies the edge between the limbic gyrus and the intralimbic gyrus, starting at the height of the fossa paracentralis and ending at the truncus fissurae parietooccipitalis et calcarinae.
LE	Occupies the intralimbic gyrus starting at the height of the fossa paracentralis up to the posterior edge of the hippocampal gyrus.
OA	Anteriorly on the lateral surface this region is bordered by a line starting at the intersection between the sulcus occipitalis primus and the sulcus parietalis transversus. From this intersection the line goes down towards the ventral surface just posterior of the Incisura praeoccipitalis and continues on the medial side parallel to the calcarine sulcus to the truncus fissurae parietooccipitalis et calcarinae. Laterally, up from the aforementioned intersection, the line goes to the fissura parietooccipitalis on the superior aspect of the hemisphere and follows this fissure to the medial side. The posterior border on the lateral surface is placed parallel and just anterior of the sulcus lunatus. On the medial aspect, one line descends from the superior surface and follows the sulcus sagittalis cunei inferior until it reaches the fissura parietooccipitalis. The second border line ascends from the ventral surface and runs parallel to the calcarine sulcus, intersecting with the anterior branch point of the sulcus lingualis.
OB	Laterally occupies the zone from the edge of the occipital pole up to just anterior of the sulcus lunatus. Medially lies between the lip of the calcarine sulcus and region OA.
OC	This region occupies the walls and lip of the calcarine sulcus, as well as the occipital pole.
PA	Laterally occupies the anterior wall of the central sulcus, medially extends out from the central sulcus onto the paracentral lobule with its anterior boundary running through the fossa paracentralis. Its inferior border is defined by the sulcus callosomarginalis, ventrally it follows the ramus verticalis of the sulcus callosomarginalis back up to the dorsal aspect, where it covers a small portion of the postcentral gyrus up to the end of the sulcus postcentralis superior.
PB	This region lies on the posterior wall of the central sulcus and extends out halfway onto the paracentral lobule.
PC	Laterally this region covers the postcentral gyrus, except for the parietal operculum, medially it extends onto the paracentral

	lobule, where it covers a narrow strip 1/4th of the width of the lobule and 2/3 of the height.
PD	Is situated in the sulcus postcentralis and its branches.
PE	Laterally this region spans from a line connecting the sulcus postcentralis superior and the ramus verticalis of the sulcus callosomarginalis to a line between the sulcus parietalis transversus and the fissura parietooccipitalis. Its ventral border is formed by the edge of the sulcus interparietalis. Medially, it is located between the ramus verticalis of the sulcus callosomarginalis and the fissura parietooccipitalis, with its ventral border drawn as a curved line starting at the beginning of the ramus verticalis sulci callosomarginalis running posteriorly along the most superior point of the sulcus subparietalis down to to the fissura parietooccipitalis at the height of the anterior end of the sulcus sagittalis cunei inferior.
PF	Covers the gyrus supramarginalis, including the parietal operculum and the operculum Rolando. Its superior border is formed by the sulcus postcentralis inferior and the interparietal sulcus. The posterior border extends from the sulcus intermedius down to the inferior end of the caudal branch of the sulcus temporalis superior, from where the inferior border of the region runs to the ramus posterior fissurae Sylvii.
PG	Lies on the angular gyrus, with its anterior border formed by a line extending from the sulcus intermedius down to the end of the caudal branch of the sulcus temporalis, from where its inferior border extends to the sulcus occipitalis secundus lateralis at the height of the inferior end of the sulcus occipitalis lateralis primus. Its posterior border is formed by the sulcus occipitalis lateralis primus and the interparietal sulcus.
PH	Described as the basal portion of the parietal lobe, laterally the anterior border of this region is formed by a line stretching from the caudal branch of the superior temporal sulcus to the beginning of the main superior temporal sulcus, connecting down along the posterior end of the inferior temporal sulcus where it continues onto the ventral portion of the temporal lobe. There region PH runs all the way to the truncus fissurae parietooccipitalis et calcarinae on the medial side parallel to region OA, covering a strip of the most posterior section (1/5) of the fusiform gyrus and gyrus retrolimbicus (1/4).
TA	Covers part of the dorsal and lateral aspect of the superior temporal lobe, with its border starting at the ramus posterior fissurae Sylvii, running to the superior temporal sulcus which it follows for 1/3 of the length of the temporal lobe. There the border extends upwards to the Margo posterior sulci circularis

	insulae. The center of this region is occupied by smaller regions TB, TC and TD.
TB	Lies within region TA, only on the dorsal aspect of the superior temporal lobe. Its outer border is drawn such that region TB is not visible on the lateral view of the hemisphere. This region covers 2/3 of the dorsal superior temporal gyrus delineated by region TA. Region TC and TD are situated within TB.
TC	Is drawn to cover the middle 1/3 of region TB, it lies flush with the margo posterior sulci circularis insulae and leaves 1/5 of the most posterior surface of TB open for region TD.
TD	Is situated on the most posterior part of the dorsal surface of the superior temporal gyrus, just below the parietal operculum. Posterior-anterior it extends about 1/5 of the length of TB from the parietal operculum.
TE	The largest temporal region. Laterally this region covers the posterior part (1/3) of the superior temporal gyrus and the posterior 2/3rd of the middle and inferior temporal gyrus.
TF	Covers the anterior 4/5th of the fusiform gyrus.
TG	This region covers the anterior tip of the temporal lobe, as well as the most anterior 1/3rd of the superior, middle and inferior temporal gyrus.

Supplemental Table S2. Border definitions of the Von Economo – Koskinas regions included in the digitized atlas. The definitions used to describe the gyri and sulci have been derived from the nomenclature as used by Von Economo and Koskinas in their atlas description (von Economo and Koskinas, 1925).

Supplemental figures and legends

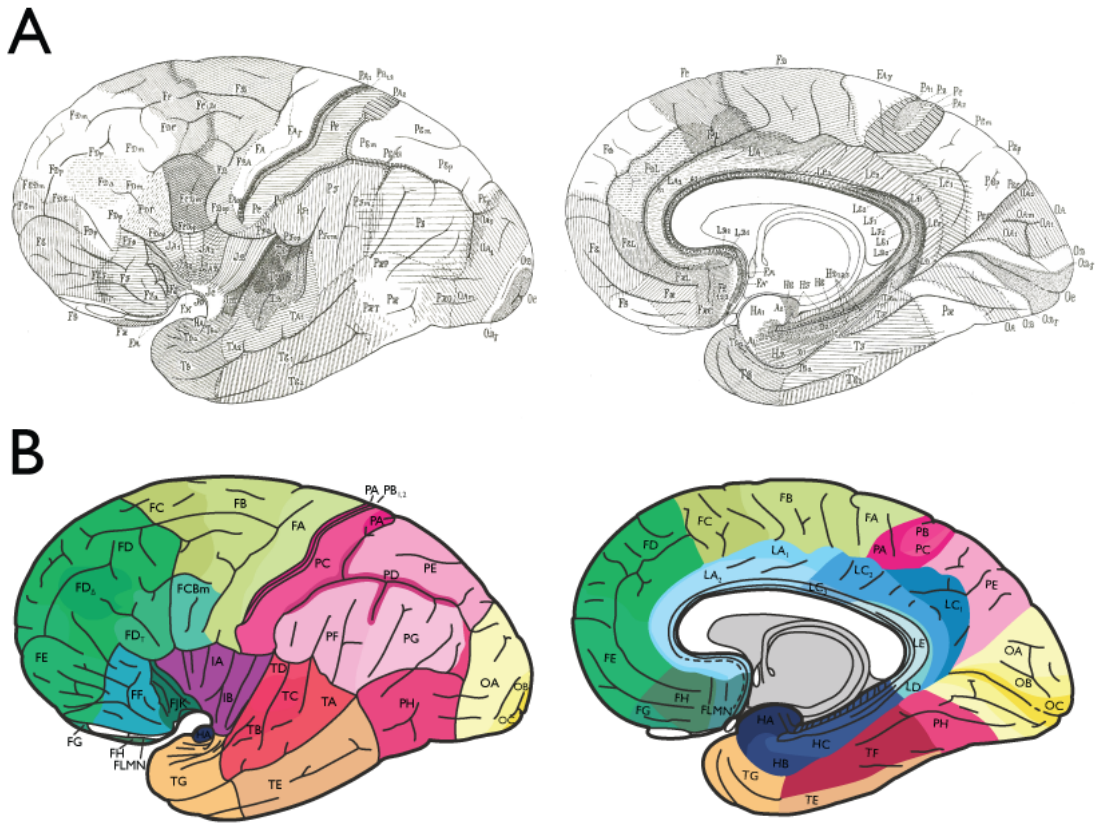

Supplemental Figure S1. Colorized version of the 1925 Von Economo – Koskinas atlas illustrations. (A) Figure shows the lateral and medial view of the original illustration described in the Von Economo – Koskinas atlas as included in their 1925 textbook (von Economo and Koskinas, 1925). **(B)** Figure shows a digitized and colored version of the illustrations showing the 43 merged regions as included in the FreeSurfer Von Economo – Koskinas atlas, which were described as the most important cortical regions and were included in the tables with histological data provided by Von Economo and Koskinas (von Economo and Koskinas, 1925).

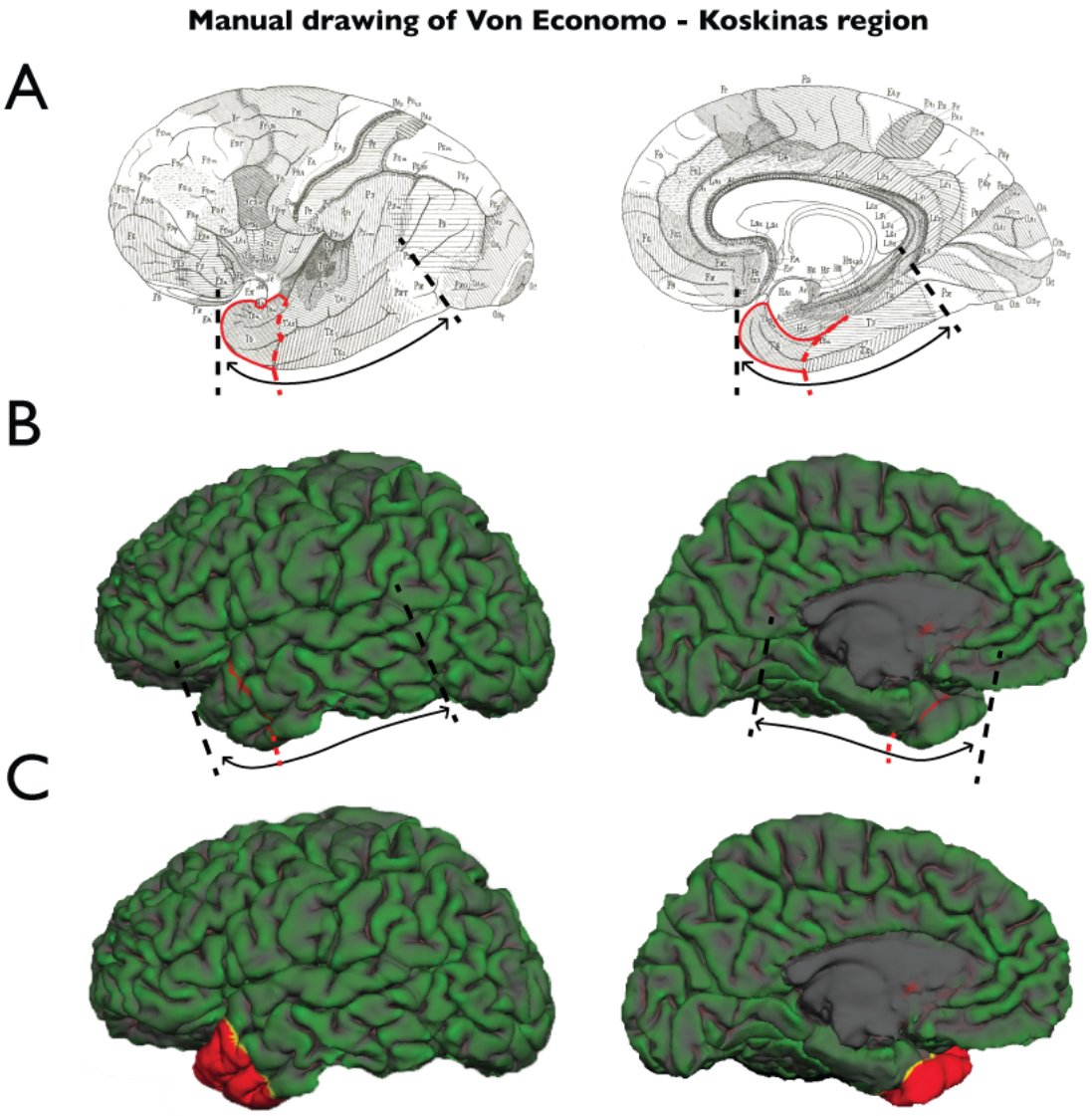

Supplemental Figure S2. Drawing cortical labels. Figure illustrates the process of drawing Von Economo – Koskinas region TG onto an exemplary cortical surface reconstruction. **(A)** Figures shows the region outlined in red on the 1925 Von Economo – Koskinas lateral and medial illustration**, (B)** the plotted outline of the region on the cortical surface reconstruction, **(C)** completed and filled-in region label.

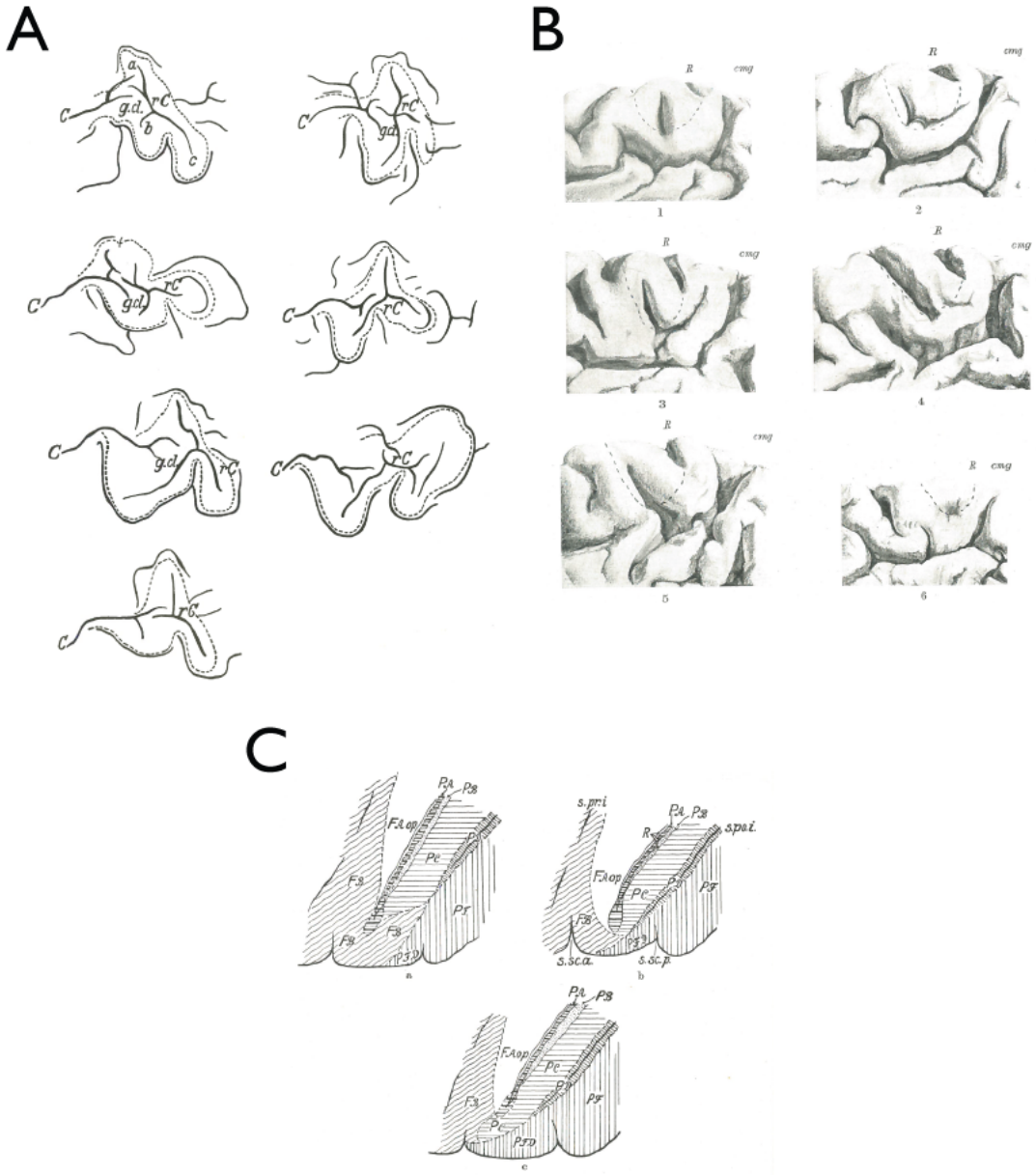

Supplemental Figure S3. Examples of variation in cortical folding. Figure shows examples of between-subject variation in cortical folding patterns, as included in the 1925 Von Economo – Koskinas textbook for **(A)** calcarine sulcus, **(B)** paracentral lobule, **(C)** central sulcus.